

Willamette Valley Inns of Court.
Judge Leith Team - "The Incredibles"-

February 1, 2017 –

FOMAC
700

Dealing With Experts – How to Present and Cross.

A. Fact Pattern –

Date of Loss- December 1, 2014.

Chester Drawers, age 49 , was a millwright that spent 25 years working at the Extinct Species lumber mill.

Chester was his way to the chiropractor for his weekly low back massage in his 1972 FORD PINTO when he was violently struck from behind by Ms. Kitty Marshall. Chester was at a complete stop waiting for the red light to turn green before he could proceed straight on Lancaster.

Both drivers got out of their vehicles and examined the vehicles. After exchanging information, the drivers continued on their way.

Mr. Drawer's Ford Pinto was totaled in the accident. Total damage estimates \$400.00.

Chester starts treating with Dr. Banger, DC on December 2, 2014 treats with the chiropractor for 4 months for problems in the lower back, neck, shoulders and feet, all related to the MVA. When the Plaintiff developed numbness and radiating pain into his right foot, Dr. Happy referred the Plaintiff to the noted neurosurgeon, Dr. Khoutom, MD. on July 1, 2015

After a brief evaluation of the lower back MRI, a 10 minute examination and a narrative of the facts of the accident, Dr. Khotum, elects to perform a 4 level fusion of the lower back. The total surgery costs were only \$150,000. The fusion Surgery was performed on July 15, 2015.

Mr. Drawers was able to walk upright and straight for the first time in years.

Chester hears from his friends that this is the time in which to strike it rich and retire. He hires a lawyer, _ to pursue his claims.

When the awful insurance company of Ms. Marshall refuses to pay for the surgery and give him his money, Mr. Drawers sues the Defendant

Timeline of the Key issues.

1. Jan 2013. – June 2014 - Chester has an extensive history of pre-existing arthritis in the lower back at multiple levels. He was treated by Dr. Absolute in 2014 for his lower back and ultimately referred to neurosurgeon Dr. Biggs, MD.

2. August 5, 2014 – Dr. Biggs, MD. recommends surgery after reviewing MRI of the lower back.

3. October 1, 2014, Chester applied for social security disability because he was unable to walk for more than 100 yards, stand for more than 30 minutes. SSD granted his request.

4. December 1, 2014 – MVA Property Damage \$500.00

4. July 1, 2015 - FIRST VISIT To Dr. Khutom. Chester does not tell Dr. Khutom, about the prior SSD disability or the problems with his back. On the Application with Dr. Khutom he notes that he had an occasional back ache but was otherwise fit.

5. July 15, 2015 - FUSION SURGERY L5- S1. Dr. Khutom, MD.

Discussion points.

1. Plaintiff Presentation of the Expert. –

A. No Theme Present consistent with Case

B. Qualifications of Expert

C. Assumptions of Expert –

1. No review of the medical records prior.

2. No review of the photographs.

3. Reliance of the Expert upon Client's statements

D. Presentation –

1. Expert not Prepared

2. No Theme of Expert

3. Not Organized – Concise

4. Checklist of Key Testimony to Accomplish

- Medically Reasonable Standard

- Medical Expenses

- Expertise

Defense Cross Examination

1. Defense Counsel Prepared –

- Review of all documents – Narrowed to those limited few.
- Documents prepared for Cross examination.

2. Identify and Attack Assumptions.

1. Identify Expert Assumptions - Not Supported by Evidence.

a. No Prior Back Issues

b. Rely on Client's statements for mechanism of Injury.

2. Attack the Expert on the Written Evidence that has.

- Use Records Medical Records
- Evidence of the Plaintiff.

3. Must BE ORGANIZED -

Stone Age Health Clinic
Dr. Maxwell Absolute, MD, MACP
Specializing in Total Health
1444 Fantasia Street, Near PDX

PATIENT - Chester Drawers

January 25, 2014 - Chester, age 49, in complaining of long time chronic lower back pain. Recent episode where he bent over to pick up his beer that had fallen over. Intense pain radiating into his foot and ankle. Pain medications, Oxycontin, 1000 mg, no longer cutting the pain. Recommend addition of the cannabis regimen to supplement pain medication plan. Cautioned about working at his job at Extinct Species lumber mill. Refer to MRI.

March 20, 2014 – MRI – revealed osteophyte protrusion at the L5- S1 level on the right side with significant intrusion into the nerve root. Multi-level degenerative problems that are significant.

July 3, 2014 – Chester concerned that he can't do his job as security job. Back pain particularly when he is awake. Pain prevents him from standing more than 1 hour or sitting. ROM is greatly restricted. Referred to Dr. Biggs for ortho evaluation.

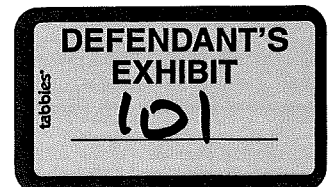
August 5, - 2014- Chart note from Dr. Biggs. Ortho pedic. Recommends that Chester have a fusion surgery at the L5- S1 levels. Discussed with Chester.

August 31, 2014, Chester in again, mumbling not really coherent. Did get it out of him that his pain is getting worse. Wants to be off of work. Not wanting surgery now... due to hunting season coming up and WWF to which he has season tickets. Gave Chester off work release for 4 months.

October 1, 2014 – Chester calls in to let me know that he has applied to SSD for low back issues. Still no surgery..

December 14, 2014 – Chester in today for renewal of pain medications, complaining of nasal congestion and rash on his belly. Mentions MVA on December 1, 2014 yesterday. Neck problems only. Seeing Chiropractor for his treatment of neck.

August 2015 – Chester in for follow-up of his outbreak of cooties. Mentions that he had fusion surgery L5- S1, with Dr. Khutom out of Portland July 1, 2015.



METAPHYSICAL SPACE VIEW DIAGNOTIC IMAGING

1000 Saturn Lane, Drive

DATE: August 2, 2014

Referring Physician : Dr. Biggs

Patient Name: Chester Drawers.

Procedure : MRI of the Lumbar Spine with Contrast.

Symptoms Complaints - Lower back pain for five years. Pain radiating down the back of the thighs, ankles. Unable to stand for more than 10 minutes. Unable to walk for more than 20 minutes.

Comparison MRI/Films- NONE

Findings.

L1-2 - Severe Osteoarthritis in encroaching into the nueuro foraminal areas and nerve roots.

L2-3 - Severe Disc Desiccation – loss of disc space, bulging Disc encroaching against the thecal sac and RIGHT to nerve root exits.

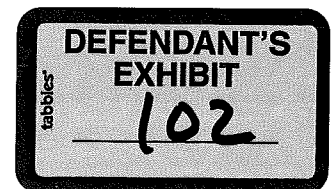
L 3-4 Severe Disc Desiccation – loss of disc space, bulging Disc encroaching against the thecal sac and RIGHT SIDE to nerve root exits.

L4-5 - Severe disc desiccation, loss of space. RIGHT tearing of the disc impinging on the nerve roots.

L 5-S1 - Severe disc desiccation, loss of space. RIGHT tearing of the disc impinging on the nerve roots.

Recommendations : Refer to Neurosurgeon Dr. Biggs for clinical confirmation of the above findings.

Dr. Travis Crawford, MD, OD, FACXCS, ITALIAN MODEL.



SOCIAL SECURITY ADMINISTRATION
APPLICATION FOR DISABILITY

THE INFORMATION CONTAINED IN THIS APPLICATION IS USED TO OBTAIN FEDERAL BENEFITS UNDER THE SSD - PART 500 PLAN. ANY FRAUDULENT STATEMENTS MADE HERE ARE PUNISHABLE BY DEATH, BEATINGS AND OTHER PSYCHOLOGICAL PUNISHMENT INCLUDING BUT NOT LIMITED TO WATCHING JUDGE JUDY AND RERUNS OF THE DATING GAME.

DATE OCTBER 1, 2014
APPLICANT'S NAME: CHESTER DRAWERS
Date of Birth: MARCH 1, 1965 Age: 49
Address: FALL CITY OREGON
Employer Name & Address: NONE -

1. REASON FOR APPLYING FOR DISABILITY:
MY LOWER BACK HURT BAD!
PAID TO REST LEG, FOOT, CAN'T WORK!

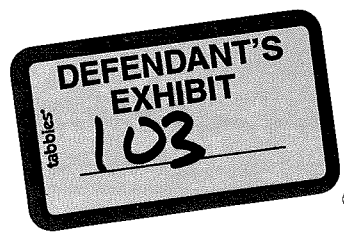
2. NUMBER OF YEARS THAT THIS CONDITION HAS EXISTED: 3 years Right?

3. WHAT MEDICAL PROVIDERS HAVE DIAGNOSED THIS CONDITION AND WHEN:
1. DR ABSOLUTE -
2. DR BIGGER - MD, SURGERY REQUIRED
3. _____

4. WORK HISTORY: MILL WRITE, EXTINCT SNEESES
23 years

5. IF THIS CONDITION WAS CAUSED BY A MOTOR VEHICLE ACCIDENT, PLEASE EXPLAIN HOW: NONE
- NO JUST WORKED TO HARD!

**Please complete the following pain diagram to show the location of the Pain.



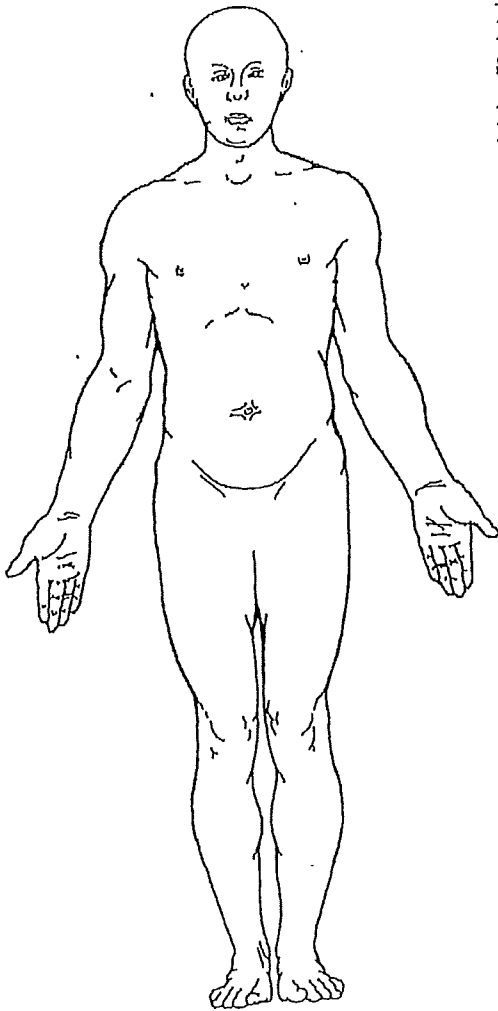
Claimant Intake Form

(Please bring completed form to exam.)

Pain Diagram

The information you provide on this form will be useful to the consultant(s) you will be seeing today and will help your exam go smoothly and as quickly as possible. If you are being evaluated for a painful condition, mark the drawings below according to how you feel today. Use the figure labeled "Back" for pain on the back of your body. If you have any of the symptoms shown in the diagram, indicate where they are by writing in the following letter on the affected body part:

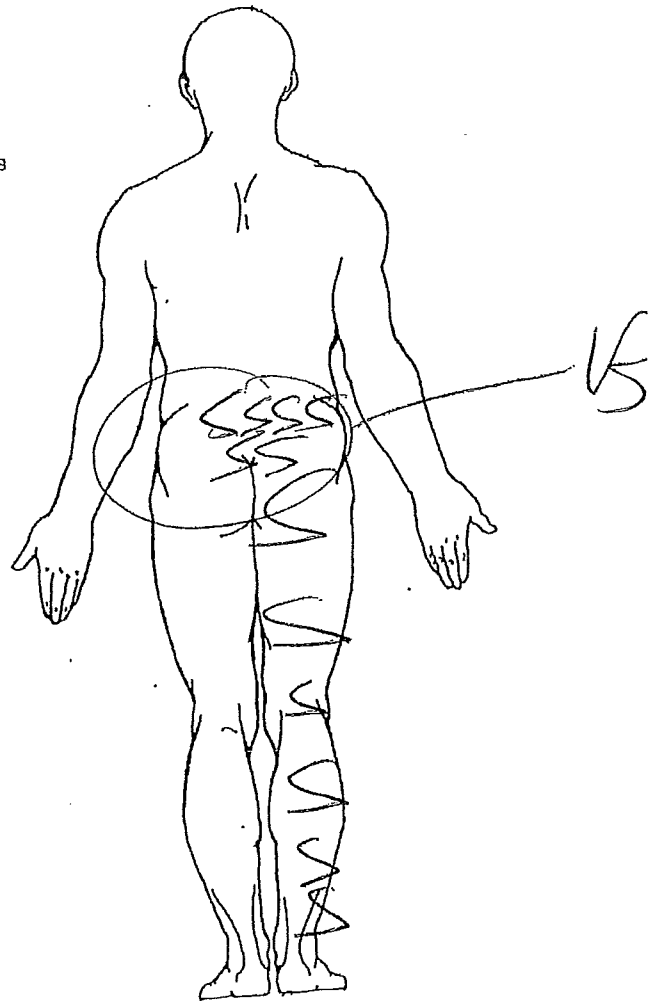
Front




Types of Pain

- B = Burning
- N = Numbness
- S = Stabbing
- A = Aching
- P = Pins & Needles

Back



Please Complete This Section
Your Name Edward Drawers Today's Date 10-1-14
Height 5-2 Weight 280 Birth Date _____ Age 49
Claim # _____



Thank you for completing this page.
Please turn to Page 4.

Dr. Khutom, MD, FAACS

Specializing in Neurosurgery for 35 years

DATE: July 1 2015

Patient Name: Chester Drawers Age 50

Address: Farm City

General Information:

1. Have you ever been treated by this office before? NO

3. Have you ever applied for Social Security Disability? NOPE

4. Who is your General Practitioner? ~~DR. ABSHUR, MD~~
DR. BRUNER DC,

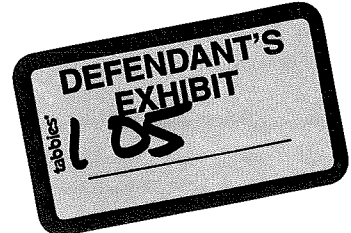
2. CURRENT CONDITIONS:

1. What is the Medical Problem that you have today?

Pain Where? PAIN RIGHT LEG, LOWER BACK
CHINA WALK, SIT STAND.

When did It Start? Dec 1. 2014

Have you had this conditions before?
Never



3. IF the cause of this accident Motor Vehicle Accident

Yes sir

What was the date of the accident?

12/1/14

How fast were you going?

0 -

How much damage to your vehicle?

TOTALLY

How were you facing?

STRAIGHT

Did you have immediate pain?

Yes. PAIN CONTINUES
TO THIS DAY

METAPHYSICAL SPACE VIEW DIAGNOTIC IMAGING

1000 Saturn Lane, Drive

DATE: July 1, 2015

Referring Physician : Dr. Khutum

Patient Name: Chester Drawers.

Procedure : MRI of the Lumbar Spine with Contrast.

Symptoms Complaints - Lower Back Pain After MVA. No Prior Problems

Comparison MRI/Films- NONE

Findings.

L1-2 - Severe Osteoarthritis in encroaching into the nueuro foraminal areas and nerve roots.

L2-3 - Severe Disc Desiccation – loss of disc space, bulging Disc encroaching against the thecal sac and bilaterally to nerve root exits.

L 3-4 Severe Disc Desiccation – loss of disc space, bulging Disc encroaching against the thecal sac and RIGHT to nerve root exits.

L4-5 - Severe disc desiccation, loss of space. RIGHT tearing of the disc impinging on the RIGHT nerve roots.

L 5-S1 - Severe disc desiccation, loss of space. RIGHT tearing of the disc impinging on the RIGHT nerve roots.

Recommendations : Refer to Neurosurgeon Dr. KHUTOM for clinical confirmation of the above findings.

Dr. Travis Crawford, MD, OD, FACXCS, ITALIAN MODEL.



Dr. Derrick Bang, DC
1234 Alphabet St.
Portland, OR 97209
(503) 540-9864

December 14, 2016

RE: Patient: Chester Drawers
DOB: January 25, 1968

To whom it may Concern

The patient, Chest Drawers, presents to my office after a severe motor vehicle collision on December 1, 2014. He describes the accident as a high speed impact. He estimates the other vehicle was traveling at a speed of 4- to 45 mph. There was substantial damage done to his vehicle with the vehicle ultimately being totaled.

Rick RB
He presented to this office complaining of neck pain, shoulder pain, mid back pain and low back pain. The low back pain radiates down into his left leg causing numbness on the lateral side of his ankle and foot. He denies having any injury to the low back or pain radiating down the left leg prior to this accident. *Rick RB*

I treated him conservatively for 88 visits of chiropractic adjustments over a course of 4 months. When his radicular pain down the left side did not continue to improve, I referred him to Dr. Khutom for surgical evaluation.

I did not see Mr. Drawers after his referral to Dr. Khatom.

All of the treatment is reasonable and related to the MVA of December 1, 2014

Sincerely

Dr. Derrick Bang, DC

