

Stone Age Health Clinic
Dr. Maxwell Absolute, MD, MACP
Specializing in Total Health
1444 Fantasia Street, Near PDX

PATIENT - Chester Drawers

January 25, 2014 - Chester, age 49, in complaining of long time chronic lower back pain. Recent episode where he bent over to pick up his beer that had fallen over. Intense pain radiating into his foot and ankle. Pain medications, Oxycontin, 1000 mg, no longer cutting the pain. Recommend addition of the cannabis regimen to supplement pain medication plan. Cautioned about working at his job at Extinct Species lumber mill. Refer to MRI.

March 20, 2014 – MRI – revealed osteophyte protrusion at the L5- S1 level on the right side with significant intrusion into the nerve root. Multi-level degenerative problems that are significant.

July 3, 2014 – Chester concerned that he can't do his job as security job. Back pain particularly when he is awake. Pain prevents him from standing more than 1 hour or sitting. ROM is greatly restricted. Referred to Dr. Biggs for ortho evaluation.

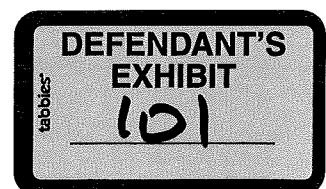
August 5, - 2014- Chart note from Dr. Biggs. Ortho pedic. Recommends that Chester have a fusion surgery at the L5- S1 levels. Discussed with Chester.

August 31, 2014, Chester in again, mumbling not really coherent. Did get it out of him that his pain is getting worse. Wants to be off of work. Not wanting surgery now... due to hunting season coming up and WWF to which he has season tickets. Gave Chester off work release for 4 months.

October 1, 2014 – Chester calls in to let me know that he has applied to SSD for low back issues. Still no surgery..

December 14, 2014 – Chester in today for renewal of pain medications, complaining of nasal congestion and rash on his belly. Mentions MVA on December 1, 2014 yesterday. Neck problems only. Seeing Chiropractor for his treatment of neck.

August 2015 – Chester in for follow-up of his outbreak of cooties. Mentions that he had fusion surgery L5- S1, with Dr. Khutom out of Portland July 1, 2015.



METAPHYSICAL SPACE VIEW DIAGNOTIC IMAGING

1000 Saturn Lane, Drive

DATE: August 2, 2014

Referring Physician : Dr. Biggs

Patient Name: Chester Drawers.

Procedure : MRI of the Lumbar Spine with Contrast.

Symptoms Complaints - Lower back pain for five years. Pain radiating down the back of the thighs, ankles. Unable to stand for more than 10 minutes. Unable to walk for more than 20 minutes.

Comparison MRI/Films- NONE

Findings.

L1-2 - Severe Osteoarthritis in encroaching into the nueuro foraminal areas and nerve roots.

L2-3 - Severe Disc Desiccation – loss of disc space, bulging Disc encroaching against the thecal sac and RIGHT to nerve root exits.

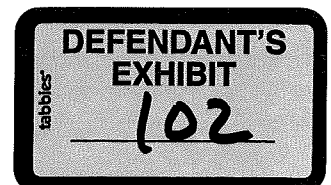
L 3-4 Severe Disc Desiccation – loss of disc space, bulging Disc encroaching against the thecal sac and RIGHT SIDE to nerve root exits.

L4-5 - Severe disc desiccation, loss of space. RIGHT tearing of the disc impinging on the nerve roots.

L 5-S1 - Severe disc desiccation, loss of space. RIGHT tearing of the disc impinging on the nerve roots.

Recommendations : Refer to Neurosurgeon Dr. Biggs for clinical confirmation of the above findings.

Dr. Travis Crawford, MD, OD, FACXCS, ITALIAN MODEL.



SOCIAL SECURITY ADMINISTRATION

APPLICATION FOR DISABILITY

THE INFORMATION CONTAINED IN THIS APPLICATION IS USED TO OBTAIN FEDERAL BENEFITS UNDER THE SSD - PART 500 PLAN. ANY FRAUDULENT STATEMENTS MADE HERE ARE PUNISHABLE BY DEATH, BEATINGS AND OTHER PSYCHOLOGICAL PUNISHMENT INCLUDING BUT NOT LIMITED TO WATCHING JUDGE JUDY AND RERUNS OF THE DATING GAME.

DATE October 1, 2014
APPLICANT'S NAME: Chester Drowers
Date of Birth: March 1, 1965 Age: 49
Address: FALL CITY OREGON
Employer Name & Address: NONE -

1. REASON FOR APPLYING FOR DISABILITY:

MY LOWER BACK HURT BAD!
PAID IN LEFT LEG, BUT, CANT WORK!

2. NUMBER OF YEARS THAT THIS CONDITION HAS EXISTED:

3 years Right!

3. WHAT MEDICAL PROVIDERS HAVE DIAGNOSED THIS CONDITION AND WHEN:

- DR ABSOLUTE -
- DR BIGGER - MD, SURGERY REQUIRED
-


4. WORK HISTORY: MILL WRITE, EXTINCT SNEECS

23 years

5. IF THIS CONDITION WAS CAUSED BY A MOTOR VEHICLE ACCIDENT, PLEASE EXPLAIN HOW: NONE

NO JUST WORKED TO HARD!

**Please complete the following pain diagram to show the location of the Pain.

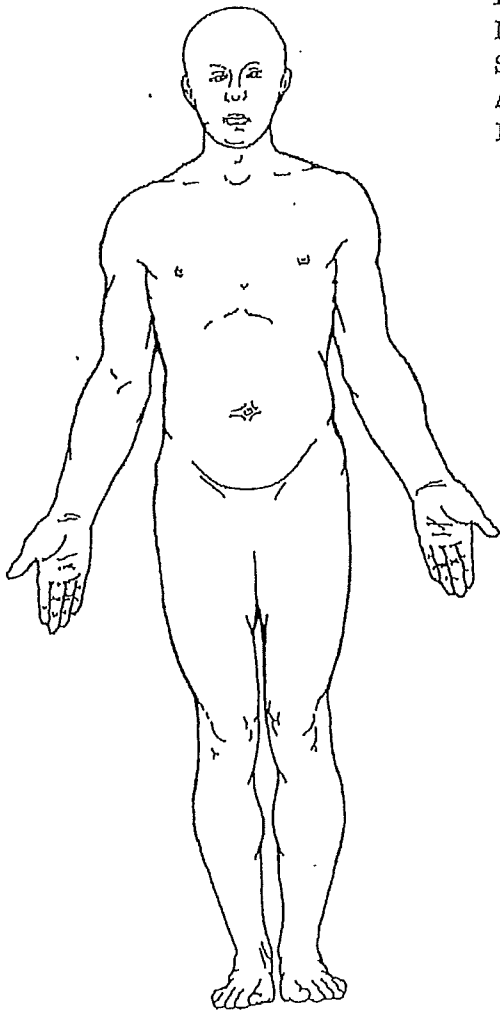


Claimant Intake Form

(Please bring completed form to exam.)

Pain Diagram
 The information you provide on this form will be useful to the consultant(s) you will be seeing today and will help your exam go smoothly and as quickly as possible. If you are being evaluated for a painful condition, mark the drawings below according to how you feel today. Use the figure labeled "Back" for pain on the back of your body. If you have any of the symptoms shown in the diagram, indicate where they are by writing in the following letter on the affected body part:

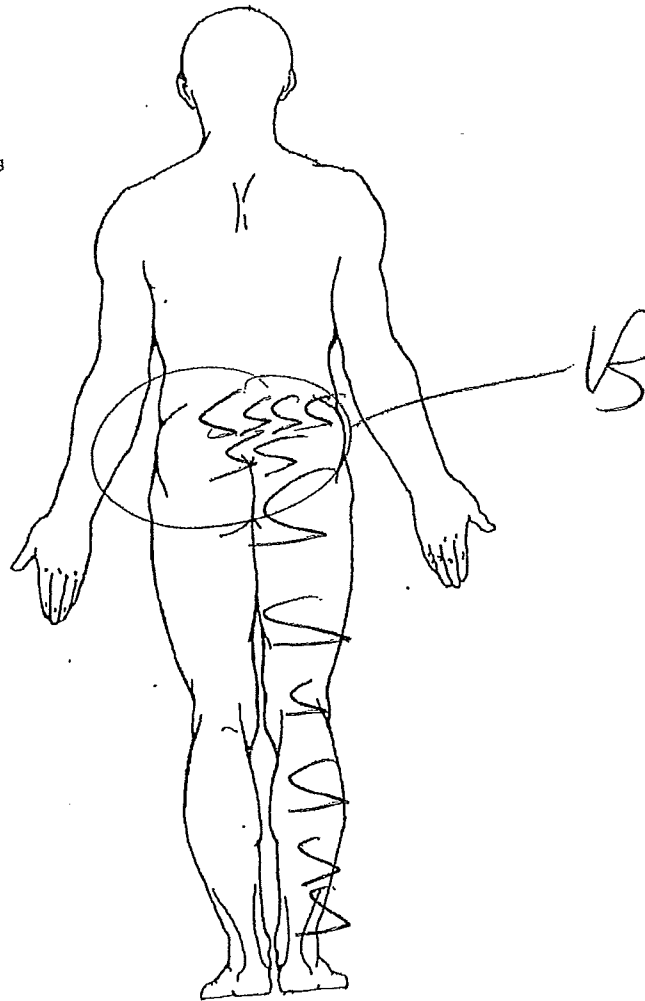
Front



Types of Pain


- B = Burning
- N = Numbness
- S = Stabbing
- A = Aching
- P = Pins & Needles

Back



Please Complete This Section
 Your Name Edward Drawers Today's Date 10-1-14
 Height 5.2 Weight 280 Birth Date _____ Age 49
 Claim # _____

Thank you for completing this page.
 Please turn to Page 4.



Dr. Khutom, MD, FAACS

Specializing in Neurosurgery for 35 years

DATE

JULY 1 2015

Patient Name: Chester Drawers Age 50

Address:

FARM CITY

General Information:

1. Have you ever been treated by this office before?

NO

3. Have you ever applied for Social Security Disability?

NOPE

4. Who is your General Practitioner?

~~DR. ABSHUR, MD~~

DR. BANNER, DC,

2. CURRENT CONDITIONS:

1. What is the Medical Problem that you have today?

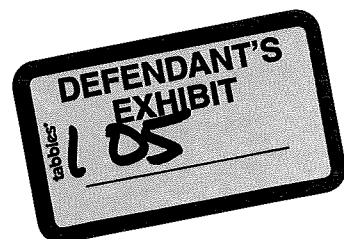Pain Where? PAIN RIGHT LEG, LOWER BACK
CANT WALK, SIT STAND.

When did It Start?

Dec 1, 2014

Have you had this conditions before?

Never



3. IF the cause of this accident Motor Vehicle Accident

Yes sure

What was the date of the accident?

12/1/14

How fast were you going?

0 -

How much damage to your vehicle?

TOTALLY

How were you facing?

STRAIGHT

Did you have immediate pain?

Yes. PAIN CONTINUES
TO THIS DAY

METAPHYSICAL SPACE VIEW DIAGNOTIC IMAGING

1000 Saturn Lane, Drive

DATE: July 1, 2015

Referring Physician : Dr. Khutum

Patient Name: Chester Drawers.

Procedure : MRI of the Lumbar Spine with Contrast.

Symptoms Complaints - Lower Back Pain After MVA. No Prior Problems

Comparison MRI/Films- NONE

Findings.

L1-2 - Severe Osteoarthritis in encroaching into the nueuro foraminal areas and nerve roots.

L2-3 - Severe Disc Desiccation – loss of disc space, bulging Disc encroaching against the thecal sac and bilaterally to nerve root exits.

L 3-4 Severe Disc Desiccation – loss of disc space, bulging Disc encroaching against the thecal sac and RIGHT to nerve root exits.

L4-5 - Severe disc desiccation, loss of space. RIGHT tearing of the disc impinging on the RIGHT nerve roots.

L 5-S1 - Severe disc desiccation, loss of space. RIGHT tearing of the disc impinging on the RIGHT nerve roots.

Recommendations : Refer to Neurosurgeon Dr. KHUTOM for clinical confirmation of the above findings.

Dr. Travis Crawford, MD, OD, FACXCS, ITALIAN MODEL.



Dr. Derrick Bang, DC
1234 Alphabet St.
Portland, OR 97209
(503) 540-9864

December 14, 2016

RE: Patient: Chester Drawers
DOB: January 25, 1968

To whom it may Concern

The patient, Chest Drawers, presents to my office after a severe motor vehicle collision on December 1, 2014. He describes the accident as a high speed impact. He estimates the other vehicle was traveling at a speed of 4- to 45 mph. There was substantial damage done to his vehicle with the vehicle ultimately being totaled.

He presented to this office complaining of neck pain, shoulder pain, mid back pain and low back pain. The low back pain radiates down into his left leg causing numbness on the lateral side of his ankle and foot. *Right RB*
He denies having any injury to the low back or pain radiating down the left leg prior to this accident. *Right DA*

I treated him conservatively for 88 visits of chiropractic adjustments over a course of 4 months. When his radicular pain down the left side did not continue to improve, I referred him to Dr. Khutom for surgical evaluation.

I did not see Mr. Drawers after his referral to Dr. Khutom.

All of the treatment is reasonable and related to the MVA of December 1, 2014

Sincerely

Dr. Derrick Bang, DC

